

For reprint orders, please contact: reprints@futuremedicine.com

Perioperative stent thrombosis

Percutaneous coronary intervention with stent placement is one of the most frequently performed procedures in the western world. Patients with coronary stents need to be on dual antiplatelet therapy in order to minimize the risk of stent thrombosis. When these patients undergo surgical procedures, the risk of stent thrombosis needs to be balanced against the risk of bleeding in the perioperative period. We review the definition of stent thrombosis and its incidence, the perioperative risk factors associated with stent thrombosis and with bleeding owing to dual antiplatelet therapy. Based on the published guidelines, we also review different management strategies of patients with coronary stents, or who develop stent thrombosis in the perioperative period. We also present some future perioperative management strategies, illustrating the possibilities and challenges offered by newer antiplatelet agents.

KEYWORDS: antiplatelet therapy ■ myocardial infarction ■ perioperative ■ stent ■ thrombosis

Syed A Raza¹,
Wanda M Popescu²
& Ion S Jovin^{*1}

¹Department of Medicine, McGuire VA Medical Center, VA, USA

²Department of Anesthesiology, Yale University School of Medicine, CT, USA

*Author for correspondence:

Department of Medicine, Virginia Commonwealth University, McGuire VAMC, 1201 Broad Rock Boulevard 11111, Richmond, VA 23249, USA
Tel.: +1 804 675 5448
Fax: +1 804 675 5450
isjovin@yahoo.com

Approximately 2 million patients undergo percutaneous coronary intervention (PCI) each year in the USA and Europe and more than 90% of these involve placement of intracoronary stents [1]. In order to minimize the risk of stent thrombosis, these patients require long-term treatment with dual antiplatelet agents (usually aspirin and clopidogrel) [2], especially when drug-eluting stents (DESs) are used. On average, approximately 5% of patients who have undergone PCI will undergo noncardiac surgery within the first year after stenting [3]. A rare but severe complication of intracoronary stent implantation is represented by stent thrombosis, which usually presents as ST-elevation myocardial infarction (STEMI), malignant arrhythmias or sudden death. It is associated with a high mortality, which ranges between 9 and 45% [4–6]. As shown by multiple studies, the most important risk factor for stent thrombosis is cessation of antiplatelet therapy. However, in order to minimize the surgical bleeding risk, preoperative discontinuation of dual antiplatelet therapy is usually required. The stress of surgery and anesthesia induces a prothrombotic state, which further increases the risk of stent thrombosis in the perioperative period. Therefore, the perioperative risk of bleeding associated with continuation of antiplatelet therapy needs to be very carefully weighed against the risk of stent thrombosis if these medications are stopped. Patients are routinely referred for coronary evaluation before noncardiac surgery. Coronary revascularization has not been convincingly shown to be beneficial

in patients without unstable anginal symptoms [7]. Therefore, the first step in perioperative management is to avoid unnecessary revascularization, which may delay surgery without a definite change in cardiovascular outcome. The real problem arises when a patient is considered for surgery after a coronary stent has been placed recently. Several issues need to be addressed regarding timing of surgery, partial or complete cessation of dual antiplatelet therapy, risk of bleeding associated with continuation of antiplatelet therapy, role of bridging therapy in the perioperative period and management of stent thrombosis, should this event occur. Therefore, in such situations, a very close collaboration is required between the surgeon, anesthesiologist and cardiologist.

Coronary stents & stent thrombosis

Percutaneous coronary intervention was first introduced in 1977, when the first percutaneous transluminal coronary angioplasty was performed on an awake patient by Andreas Gruentzig in the University Hospital Zurich (Germany). Until the early 1990s, balloon angioplasty remained the only percutaneous coronary revascularization procedure available for the treatment of coronary artery disease. The main complication of the procedure is acute vessel occlusion, caused by vascular recoil and spasm, and manifested as myocardial infarction or sudden death. In order to circumvent this problem, coronary stents were developed. Another potential complication alleviated by stents is arterial dissection.

future
medicine part of fsg

Placement of bare-metal stents (BMSs) reduced the need for reinterventions considerably, but the deployment of such devices was associated with neointimal hyperplasia, which ultimately led to in-stent restenosis. Subsequently, DESs were developed, targeting the neointimal hyperplasia process and, thus, reducing the in-stent restenosis rates. Both BMSs and DESs have been associated with stent thrombosis, which is a platelet-mediated phenomenon. The incidence of stent thrombosis is low, ranging between 0.9 and 1.3% [4,6], but when it occurs, it is usually associated with a high risk of mortality. Recent studies have suggested that DESs may be associated with slightly higher risk of late stent thrombosis compared with BMSs [8]. While the current recommendations for dual antiplatelet therapy for DES is 12 months, studies are ongoing regarding the optimal duration of antiplatelet therapy with newer DESs, which are thought to be safer.

The definition of stent thrombosis varied among different trials and, therefore, led to inconsistencies in reporting of this complication. In 2006, the Academic Research Consortium, formed from academic research organizations in the USA and Europe, reached a consensus in end point definitions [9]. According to the Consortium, stent thrombosis is defined in terms of level of evidence and timing of events (Box 1).

According to the Consortium, stent thrombosis should be stratified, both according to level of certainty and timing of events, to define varying degrees of certainty and to imply different pathophysiological mechanisms involved in the event.

Risk factors for stent thrombosis

Certain features are associated with higher risk of stent thrombosis [4,6,10–12]. These can be broadly divided into patient-related and procedural factors (Box 2).

Of these, the most important risk factor for stent thrombosis is cessation of (dual) antiplatelet therapy. In one series of patients with DES thrombosis, premature cessation of antiplatelet therapy was associated with a hazard ratio of 90 [6]. The most important procedural factors are stent underexpansion and residual dissection.

■ Perioperative bleeding risks associated with antiplatelet therapy

In surgical patients, hemorrhagic risk needs to be assessed initially, independent of antiplatelet regimen. Surgeries can be classified into low,

medium or high hemorrhagic risk, according to the need for blood transfusion and possibility of bleeding in a closed space (TABLE 1) [13].

Balancing the risk of surgical hemorrhage with continuation of antiplatelet therapy with that of stent thrombosis (if antiplatelet therapy is withdrawn) is a critical step in the perioperative management of patients with coronary stents. There are several important points that must be taken into consideration when weighing up the risks of both maintaining and withdrawing antiplatelet drugs [14–16]. The maintenance of antiplatelet drugs is associated with an average increase of 2.5–20% in surgical blood loss when aspirin alone is maintained (30–50% when aspirin is coadministered with clopidogrel), and an average increase of 30% in transfusion rate. The risks of withdrawing antiplatelet drugs are a high mortality rate associated with stent thrombosis, particularly if the surgery is performed early after stent implantation, and a rebound effect with increased platelet adhesiveness, leading to increased infarction and death rates in acute coronary syndrome (ACS) patients.

Several studies have demonstrated that, even though there was an increase in surgical hemorrhage and transfusion requirement with antiplatelet drugs, therapy with antiplatelet agents was not associated with changes in mortality or surgical outcome, except in intracranial surgery [3,17–19]. On the other hand, studies have reported a very high mortality rate associated with postoperative myocardial infarction (MI) owing to stent thrombosis, ranging from 20 to 80% [18,20]. Therefore, the risk of stent thrombosis may outweigh the risk of excessive hemorrhage in a vast majority of patients undergoing noncardiac surgery (TABLE 2).

Strategies for the prevention of perioperative stent thrombosis

There are two clinical scenarios that are usually encountered in the perioperative setting. First, the patient is referred for preoperative cardiac evaluation for noncardiac surgery and is being considered for coronary revascularization. Second, which is more common, the patient with a previous coronary stent presents for noncardiac surgery.

For the first scenario, two trials did not show increased benefit of coronary revascularization in patients undergoing vascular surgery compared with optimal medical therapy [7,21]. Therefore, revascularization, especially with stent placement, may not be required in patients scheduled for noncardiac surgery, if they do not

have high-risk clinical features, such as unstable angina, acute decompensated heart failure or unstable cardiac rhythm abnormalities.

Regarding the second scenario, there are several factors that need to be balanced in terms of urgency of surgery, timing and type of stent, risk of surgical hemorrhage and risk factors associated with stent thrombosis. The strategies now mentioned pertain to the second scenario (FIGURE 1).

■ Delaying surgery

Studies have demonstrated that in patients with a BMS, the risk of stent thrombosis is highest in the first 6 weeks of stent implantation, after which time the risk lowers considerably [17,18,20,22]. Therefore, in these patients, elective surgery should be delayed for at least 6 weeks following stent implantation. Nuttal *et al.* demonstrated that risk for major adverse cardiovascular events is lowest (2.8%) if noncardiac surgery is performed 90 days after percutaneous coronary intervention (PCI) with BMS [23]. For DESs, optimal delay is not clearly defined, but most groups, including the American College of Cardiology (ACC) and the American Heart Association (AHA), recommend delaying elective surgery for at least 1 year. In addition, a study by van Kuijk *et al.* had similar conclusions; noncardiac surgery after PCI with a BMS is associated with a lower risk when the surgery is performed at 90 days or more after the PCI [24]. The decision to continue antiplatelet therapy is independent, and is described in detail in the following sections.

■ Continuing both aspirin & clopidogrel during surgery

The approach of continuing both aspirin and clopidogrel during surgery is associated with the lowest risk of stent thrombosis in the perioperative period, and should be preferable for most low- and intermediate-risk surgeries [25,26]. Close coordination between the surgeon, cardiologist and anesthesiologist is essential to ensure compliance with dual antiplatelet therapy in such patients. This applies to most surgeries, including general surgeries, endoscopies, anterior chamber eye surgeries, minor orthopedic and ear, nose and throat surgeries, dental extractions and dermatological surgeries. In most of these surgeries, excess bleeding associated with antiplatelet therapy can be stopped with local measures, and discontinuation of antiplatelet therapy is not necessary [27,28]. If the surgeons are made aware of the risk of stent thrombosis and its high mortality, most of them

Box 1. Classification of stent thrombosis.

Trilevel of certainty classification

- Definite stent thrombosis: angiographic or pathologic confirmation required
- Probable stent thrombosis: any unexplained death within 30 days of stent implantation or any myocardial infarction in the territory of implanted stent
- Possible stent thrombosis: any unexplained death from 30 days to end of trial follow-up

Stent thrombosis: timing classification

- Acute stent thrombosis: within the first 24 h of stent implantation
- Subacute stent thrombosis: >24 h to 30 days after stent implantation
- Late stent thrombosis: >30 days to 1 year after stent implantation
- Very-late stent thrombosis: >1 year after stent implantation

will be willing to deal with the risk of excess bleeding, and continue the patient on aspirin and clopidogrel.

■ Stopping clopidogrel & continuing aspirin

The ‘stopping clopidogrel and continuing aspirin’ approach is most reasonable for patients in whom stent implantation was not performed recently (6 weeks for BMS and 1 year for DES). In patients with no/minimal high-risk features associated with stent thrombosis, if the surgical risk of bleeding is high, it may be reasonable to stop clopidogrel and continue aspirin. Maintaining aspirin monotherapy will reduce the rate of stent thrombosis, but will not eliminate it. Clopidogrel should be restarted as soon as possible after surgery, with a loading dose of 300–600 mg [25,26]. However, if the risk of stent thrombosis is high, or surgery is required soon after stent implantation, ‘bridging therapy’ can be considered as an alternative.

■ Bridging therapy

Bridging therapy has been described in patients faced with the dilemma of having a coronary

Box 2. Risk factors for stent thrombosis.

Patient-related factors

- Cessation of antiplatelet therapy
- Acute coronary syndrome
- Reduced left ventricular ejection fraction
- Diabetes mellitus
- Renal insufficiency
- Genetic factors
- Hypercoagulable states

Procedural factors

- Stent underexpansion
- Side-branch occlusion
- Incomplete stent apposition
- Residual dissection
- Multiple stents
- Type C lesion
- Increased length of lesion
- Bifurcation lesion

Table 1. Classification of surgical procedures according to bleeding risk.

Hemorrhagic risk	Transfusion requirement	Type of surgery
Low risk	Usually not required	General, plastic and peripheral surgery, biopsies, minor orthopedic, ear, nose and throat, endoscopy, dental extraction and eye anterior chamber
Intermediate risk	Frequently required	Cardiovascular and visceral surgery, major orthopedic, ear, nose and throat and endoscopic urology
High risk	Possible bleeding in a closed space	Intracranial and spinal canal surgery, posterior chamber eye surgery

stent, placed recently, who will have noncardiac surgery and have a high hemorrhagic risk. In these patients, clopidogrel needs to be stopped 5 days prior to surgery and aspirin continued. Bridging with heparin and aspirin was not shown to be effective. In addition, bleeding and rebound hypercoagulability associated with

heparin therapy makes heparin a less desirable agent for bridging and, therefore, is not recommended [29,30]. There have been case reports and case series of short-acting GpIIb/IIIa, used as a bridge with aspirin, with some success [29,31]. A recent Phase II trial demonstrated promising results with a GpIIb/IIIa agent, tirofiban,

Table 2. Outcomes of patients with stents in the perioperative period.

Study	Type	Patients (n)	Stent type	Time from PCI to surgery	AP treatment prior to surgery	AP treatment perioperatively	Outcome	Ref.
Kaluza <i>et al.</i> (2000)	R	40	BMS	1–39 days	ASA + ticlopidine	Most patients discontinued both	ST in 7 patients, 20% mortality	[20]
Wilson <i>et al.</i> (2003)	R	207	BMS	<60 days	ASA + ticlopidine or plavix or warfarin	26% dual AP, 65% ASA only, 6% no AP, 2% ASA + warfarin	ST in 8 patients, 4% mortality	[17]
Sharma <i>et al.</i> (2004)	R	47	BMS	<90 days	ASA + ticlopidine or clopidogrel	Thienopyridines stopped in 25% of patients 5 days prior to surgery	ST in 7 patients	[18]
Reddy <i>et al.</i> (2005)	R	56	BMS	0 to >42 days	ASA + clopidogrel	79% on ASA and 32% on clopidogrel	MACE in 8 patients, 5/8 had thrombosis driven MACE	[22]
Vicenzi <i>et al.</i> (2006)	R	103	BMS + DES	<1 year	ASA + clopidogrel	ASA ± clopidogrel continued or discontinued <3 days before surgery	44 patients with cardiac events, 4.9% mortality	[3]
Compton <i>et al.</i> (2006)	R	38	DES	Median 9 months	ASA + clopidogrel	ASA and clopidogrel continued in 78 and 41%, respectively	0% event rate	[40]
Kim <i>et al.</i> (2007)	R	239	BMS + DES	<2 years	ASA + clopidogrel	AP stopped 5–7 days before surgery	ST: 3/138 (2.2%) in DES group 0/101 in BMS group	[41]
Schouten <i>et al.</i> (2007)	R	192	BMS + DES	<2 years	ASA + clopidogrel	AP stopped in all patients with MACE	ST in 5 patients, all fatal	[42]
Rabbits <i>et al.</i> (2008)	R	520	DES	<2 years	ASA + thienopyridine	ASA and thienopyridine continued in 365 and 175 patients, respectively	MACE in 28 patients, ST in 4 patients	[43]
Godet <i>et al.</i> (2008)	R	96	BMS + DES	1 week to 36 months	ASA + clopidogrel	ASA stopped in 29 and clopidogrel stopped in 59	MI in 12 patients ST in 2 patients	[44]
Assali <i>et al.</i> (2009)	R	78	DES	183–1125 days	ASA + clopidogrel	ASA stopped in 82%, clopidogrel stopped in 58%	MACE in 6 patients ST in 2 patients	[45]
Savonitto <i>et al.</i> (2010)	P	30	DES	1–12 months	ASA + clopidogrel	Clopidogrel stopped 5 days before surgery in all patients 'bridged' with tirofiban	No ST, death or MI	[32]

AP: Antiplatelet; ASA: Aspirin; BMS: Bare-metal stent; DES: Drug-eluting stent; MACE: Major adverse cardiovascular events; MI: Myocardial infarction; P: Prospective; PCI: Percutaneous coronary intervention; R: Retrospective; ST: Stent thrombosis.

used as a bridge to surgery [32]. In this trial, 30 patients had clopidogrel 5 days prior to surgery and tirofiban started 1 day after stopping clopidogrel. Tirofiban was continued until 4 h before surgery, and resumed 2 h after surgery until oral clopidogrel was resumed. There were no cases of death, MI, stent thrombosis or surgical re-exploration. Based on this, and several other case reports and series [27,29], bridging therapy with GpIIb/IIIa, with or without aspirin, may be an acceptable option when faced with the aforementioned situation. It should be noted that this is not endorsed by ACC/AHA yet and is a costly method, involving admission to the hospital for several days prior to surgery.

Strategies for the management of perioperative stent thrombosis

Stent thrombosis frequently presents as a STEMI, and early reperfusion is the best treatment. In the perioperative period, reperfusion with a thrombolytic is not possible, owing to the excess risk of bleeding in most cases. As a general rule, thrombolytics are less effective than primary PCI among all patients with STEMI; therefore, primary PCI is the treatment of choice for perioperative stent thrombosis. Owing to the high mortality associated with stent thrombosis, noncardiac surgery in patients with recent coronary stents, should preferably be performed in a hospital with a cardiac catheterization laboratory with primary PCI facilities. The anesthesiologist needs to be aware of the different presentations of stent thrombosis, and timely activation of cardiac catheterization laboratory is vital [25,33].

Conclusion

Stent thrombosis is a platelet-mediated phenomenon that usually presents as STEMI, malignant arrhythmias or death and is associated with very high mortality. Premature cessation of antiplatelet therapy is the most important risk factor for stent thrombosis. Noncardiac surgery induces a prothrombotic state, increasing the risk of stent thrombosis. Stent thrombosis risk is highest in the first 6 weeks after coronary stent implantation; therefore, only emergent surgeries should be performed during this time. All elective procedures should be delayed for at least 6 weeks after BMS and ideally, for 12 months after DES placement. A team-based approach is important, with close coordination between the cardiologist, the anesthesiologist and the surgeon. Dual antiplatelet therapy should be continued if the perioperative bleeding risk is low. Newer antiplatelet

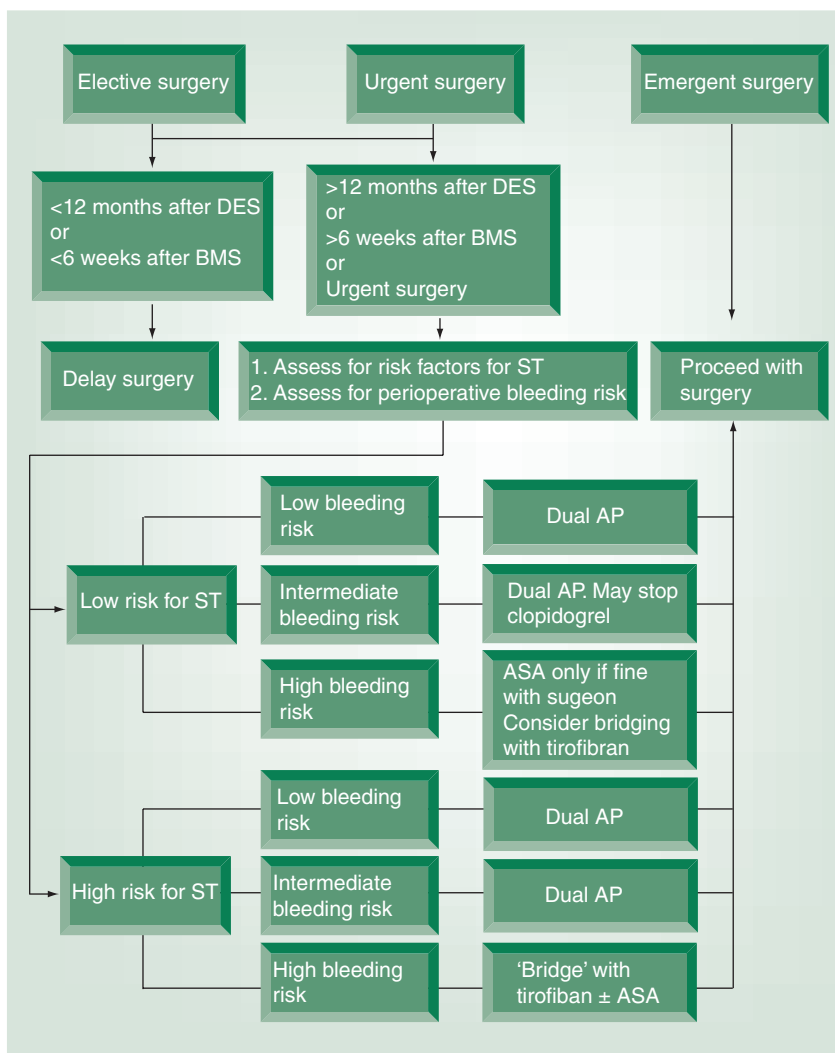


Figure 1. Decision tree for perioperative management of patients with coronary stents. AP: Antiplatelet therapy; ASA: Aspirin; BMS: Bare-metal stent; DES: Drug-eluting stent; ST: Stent thrombosis.

agents with short half-lives and rapid onset of action may provide a solution for patients with coronary stents who have a semiurgent indication for surgery.

Future perspective

A number of novel antiplatelet agents are being introduced in clinical practice, some of which may be of use in the perioperative management of patients with coronary stents. Prasugrel is a novel oral thienopyridine prodrug, which has a much more potent, rapid and consistent platelet-inhibition activity compared with clopidogrel [34,35]. In the recently published Trial to Assess Improvement in Therapeutic Outcomes by Optimizing Platelet Inhibition with Prasugrel–Thrombolysis in Myocardial Infarction (TRITON–TIMI) study, the incidence of stent thrombosis was 2.4% with

clopidogrel and 1.1% with prasugrel [36]. However, prasugrel use was associated with an increased risk of fatal bleeding especially in a subset of patients who were aged older than 75 years, weighed less than 130 lb or had a previous history of stroke. A similar trend was observed in the Prasugrel in Comparison to Clopidogrel for Inhibition of Platelet Activation and Aggregation – Thrombolysis in Myocardial Infarction 44 Trial (PRINCIPLE-TIMI 44) [37]. Given the high bleeding risk, prasugrel may be of limited value in the perioperative management of patients with stent. One potential use may be in the treatment of stent thrombosis postoperatively when rapid platelet inhibition is desired and can be achieved by prasugrel more effectively.

Ticagrelor is another novel oral antiplatelet agent. It is a nonthienopyridine ADP analog, which does not require metabolic activation, and binds directly and reversibly to the P2Y₁₂ platelet receptor. In the Study of Platelet Inhibition and Patient Outcomes (PLATO), stent thrombosis was reduced to 2.9% with ticagrelor compared with 3.8% with clopidogrel, without a significant increase in bleeding [38]. Ticagrelor has a relatively short half-life (6–13 h) and rapid onset of action, which makes it an attractive

option for the perioperative period [39]. Patients with stents can stop ticagrelor 1 day prior to surgery, and resume it soon afterwards.

Cangrelor is another new antiplatelet agent that is administered intravenously. It has a very short half-life (3 min), which makes it an ideal agent for bridging. It has a rapid onset of action and greater platelet inhibition compared with clopidogrel [39]. The ongoing BRIDGE trial is aiming to show the safety of cangrelor in the perioperative period. Given the fact that it is an intravenous medication, patients would need to be admitted before surgery, and started on an intravenous infusion that can be stopped a few minutes before surgery and started soon afterwards. This drug has a lot of promise in the perioperative management of patients with stents given its clinical profile.

Financial & competing interests disclosure

The authors have no relevant affiliations or financial involvement with any organization or entity with a financial interest in or financial conflict with the subject matter or materials discussed in the manuscript. This includes employment, consultancies, honoraria, stock ownership or options, expert testimony, grants or patents received or pending, or royalties. No writing assistance was utilized in the production of this manuscript.

Executive summary

- Coronary revascularization with stent placement is a common procedure, and patients frequently present for surgical procedures after a recently placed coronary stent.
- Stent thrombosis is a feared complication of stent implantation associated with high mortality and morbidity.
- The most important risk factor for stent thrombosis is premature cessation of antiplatelet therapy, and balancing the risk of stent thrombosis with that of perioperative bleeding associated with use of antiplatelet medications is often difficult.
- Continuing dual antiplatelet therapy is feasible for most surgeries with low-to-moderate surgical hemorrhagic risk.
- Heparin use as bridging therapy has not been shown to be effective but recent evidence suggests that GpIIb/IIIa bridging may be an alternative when antiplatelet agents need to be discontinued for surgery.
- Newer antiplatelet agents, such as ticagrelor and cangrelor, may prove to be useful in the perioperative setting, owing to their pharmacokinetics.

Bibliography

Papers of special note have been highlighted as:

▪ of interest

▪▪ of considerable interest

- 1 Steinhubl S, Berger P, Mann JT *et al.*: Early and sustained dual oral antiplatelet therapy following percutaneous coronary intervention: a randomized controlled trial. *JAMA* 288(19), 2411–2420 (2002).
- 2 Schror K: Clinical pharmacology of the adenosine diphosphate (ADP) receptor antagonist, clopidogrel. *Vasc. Med.* 3(3), 247–251 (1998).
- 3 Vicenzi MN, Meislitzer T, Heitzinger B *et al.*: Coronary artery stenting and non-cardiac surgery – a prospective outcome study. *Br. J. Anaesth.* 96(6), 686–693 (2006).
- 4 Cutlip DE, Baim DS, Ho KK *et al.*: Stent thrombosis in the modern era: a pooled analysis of multicenter coronary stent clinical trials. *Circulation* 103(15), 1967–1971 (2001).
- 5 Ong ATL, McFadden E, Regar E *et al.*: Late angiographic stent thrombosis (LAST) events with drug-eluting stents. *J. Am. Coll. Cardiol.* 45(12), 2088–2092 (2005).
- 6 Iakovou I, Schmidt T, Bonizzi E *et al.*: Incidence, predictors, and outcome of thrombosis after successful implantation of drug-eluting stents. *JAMA* 293(17), 2126–2130 (2005).
- 7 McFalls E, Ward H, Moritz T *et al.*: Coronary-artery revascularization before elective major vascular surgery. *N. Engl. J. Med.* 351(27), 2795–2804 (2004).
- 8 Jensen L, Maeng M, Kaltoft A *et al.*: Stent thrombosis, myocardial infarction, and death after drug-eluting and bare-metal stent coronary interventions. *J. Am. Coll. Cardiol.* 50(5), 463–470 (2007).
- Landmark trial observing incidence, predictors and outcomes of stent thrombosis after drug-eluting stents in real-world patients.

- 9 Cutlip D, Windecker S, Mehran R *et al.*: Clinical end points in coronary stent trials: a case for standardized definitions. *Circulation* 115(17), 2344–2351 (2007).
- **Describes consensus criteria for clinical end-point definitions to provide consistency in coronary stent trials.**
- 10 Kuchulakanti P, Chu W, Torguson R *et al.*: Correlates and long-term outcomes of angiographically proven stent thrombosis with sirolimus- and paclitaxel-eluting stents. *Circulation* 113(8), 1108–1113 (2006).
- 11 Luscher T, Steffel J, Eberli F *et al.*: Drug-eluting stent and coronary thrombosis: biological mechanisms and clinical implications. *Circulation* 115(8), 1051–1058 (2007).
- 12 Park D, Park S, Park K *et al.*: Frequency of and risk factors for stent thrombosis after drug-eluting stent implantation during long-term follow-up. *Am. J. Cardiol.* 98(3), 352–356 (2006).
- 13 Chassot P, Delabays A, Spahn DR: Perioperative antiplatelet therapy: the case for continuing therapy in patients at risk of myocardial infarction. *Br. J. Anaesth.* 99(3), 316–328 (2007).
- 14 Chassot P, Delabays A, Spahn D: Perioperative use of antiplatelet drugs. Best practice research. *Clin. Anaesthesiol.* 21(2), 241–256 (2007).
- **Excellent review comparing the risk of bleeding with different antiplatelet agents and risk of stent thrombosis if those agents are stopped.**
- 15 Collet JP, Montalescot G, Blanchet B *et al.*: Impact of prior use or recent withdrawal of oral antiplatelet agents on acute coronary syndromes. *Circulation* 110(16), 2361–2367 (2004).
- 16 Vial JH, McLeod LJ, Roberts MS: Rebound elevation in urinary thromboxane B2 and 6-keto-PGF1 α excretion after aspirin withdrawal. *Adv. Prostaglandin Thromboxane Leukot. Res.* 21A, 157–160 (1991).
- 17 Wilson S, Fasseas P, Orford J *et al.*: Clinical outcome of patients undergoing non-cardiac surgery in the two months following coronary stenting. *J. Am. Coll. Cardiol.* 42(2), 234–240 (2003).
- 18 Sharma A, Ajani A, Hamwi S *et al.*: Major noncardiac surgery following coronary stenting: when is it safe to operate? *Catheter. Cardiovasc. Interv.* 63(2), 141–145 (2004).
- 19 Qureshi A, Saad M, Zaidat O *et al.*: Intracerebral hemorrhages associated with neurointerventional procedures using a combination of antithrombotic agents including abciximab. *Stroke* 33(7), 1916–1919 (2002).
- 20 Kałuza GL, Joseph J, Lee JR *et al.*: Catastrophic outcomes of noncardiac surgery soon after coronary stenting. *J. Am. Coll. Cardiol.* 35(5), 1288–1294 (2000).
- 21 Poldermans D, Schouten O, Vidakovic R *et al.*: A clinical randomized trial to evaluate the safety of a noninvasive approach in high-risk patients undergoing major vascular surgery: the DECREASE-V pilot study. *J. Am. Coll. Cardiol.* 49(17), 1763–1769 (2007).
- 22 Reddy P, Vaitkus P: Risks of noncardiac surgery after coronary stenting. *Am. J. Cardiol.* 95(6), 755–757 (2005).
- 23 Nuttall G, Brown M, Stombaugh J *et al.*: Time and cardiac risk of surgery after bare-metal stent percutaneous coronary intervention. *Anesthesiology* 109(4), 588–595 (2008).
- **Demonstrates that the risk of major adverse coronary events is lowest when noncardiac surgery is performed 90 days after percutaneous coronary intervention with bare-metal stent.**
- 24 van Kuijk J, Flu W, Schouten O *et al.*: Timing of noncardiac surgery after coronary artery stenting with bare metal or drug-eluting stents. *Am. J. Cardiol.* 104(9), 1229–1234 (2009).
- 25 Abualsaud A, Eisenberg M: Perioperative management of patients with drug-eluting stents. *JACC Cardiovasc. Interv.* 3(2), 131–142 (2010).
- **Good overview of management of patients in the perioperative setting with drug-eluting stent only.**
- 26 Brilakis E, Banerjee S, Berger P: Perioperative management of patients with coronary stents. *J. Am. Coll. Cardiol.* 49(22), 2145–2150 (2007).
- 27 Brennan MT, Valerin MA, Noll JL *et al.*: Aspirin use and post-operative bleeding from dental extractions. *J. Dent. Res.* 87(8), 740–744 (2008).
- 28 Grines C, Bonow R, Casey D *et al.*: Prevention of premature discontinuation of dual antiplatelet therapy in patients with coronary artery stents: a science advisory from the American Heart Association, American College of Cardiology, Society for Cardiovascular Angiography and Interventions, American College of Surgeons, and American Dental Association, with representation from the American College of Physicians. *J. Am. Coll. Cardiol.* 49(6), 734–739 (2007).
- 29 Broad L, Lee T, Conroy M *et al.*: Successful management of patients with a drug-eluting coronary stent presenting for elective, non-cardiac surgery. *Br. J. Anaesth.* 98(1), 19–22 (2007).
- 30 Dent H, Lekic Z, Vicenzi M: Unfractionated heparin and coronary artery stenting. *Br. J. Anaesth.* 97(4), 582 (2006).
- 31 Bigalke B, Seizer P, Geisler T *et al.*: Perioperative antiplatelet therapy in patients at risk for coronary stent thrombosis undergoing noncardiac surgery. *Clin. Res. Cardiol.* 98(5), 335–339 (2009).
- 32 Savonitto S, D'Urbano M, Caracciolo M *et al.*: Urgent surgery in patients with a recently implanted coronary drug-eluting stent: a Phase II study of 'bridging' antiplatelet therapy with tirofiban during temporary withdrawal of clopidogrel. *Br. J. Anaesth.* 104(3), 285–291 (2010).
- **First positive trial of 'bridging therapy' with GpIIb/IIIa in patients undergoing surgery after recent drug-eluting stent.**
- 33 Popescu W: Perioperative management of the patient with a coronary stent. *Curr. Opin. Anaesthesiol.* 23(1), 109–115 (2010).
- 34 Weerakkody G, Jakubowski J, Brandt J *et al.*: Comparison of speed of onset of platelet inhibition after loading doses of clopidogrel versus prasugrel in healthy volunteers and correlation with responder status. *Am. J. Cardiol.* 100(2), 331–336 (2007).
- 35 Weerakkody G, Jakubowski J, Brandt J *et al.*: Greater inhibition of platelet aggregation and reduced response variability with prasugrel versus clopidogrel: an integrated analysis. *J. Cardiovasc. Pharmacol. Ther.* 12(3), 205–212 (2007).
- 36 Wiviott S, Braunwald E, McCabe C *et al.*: Prasugrel versus clopidogrel in patients with acute coronary syndromes. *N. Engl. J. Med.* 357(20), 2001–2015 (2007).
- 37 Wiviott S, Trenk D, Frelinger A *et al.*: Prasugrel compared with high loading- and maintenance-dose clopidogrel in patients with planned percutaneous coronary intervention: the Prasugrel in Comparison to Clopidogrel for Inhibition of Platelet Activation and Aggregation – Thrombolysis in Myocardial Infarction 44 trial. *Circulation* 116(25), 2923–2932 (2007).
- 38 Wallentin L, Becker R, Budaj A *et al.*: Ticagrelor versus clopidogrel in patients with acute coronary syndromes. *N. Engl. J. Med.* 361(11), 1045–1057 (2009).
- 39 Angiolillo D, Capranzano P: Pharmacology of emerging novel platelet inhibitors. *Am. Heart J.* 156(Suppl. 2), S10–S15 (2008).
- 40 Compton PA, Zankar A, Adesanya A *et al.*: Risk of noncardiac surgery after coronary drug-eluting stent implantation. *Am. J. Cardiol.* 98(9), 1212–1213 (2006).

- 41 Kim H, Park K, Kwak J *et al.*: Stent-related cardiac events after non-cardiac surgery: drug-eluting stent vs. bare metal stent. *Int. J. Cardiol.* 123(3), 353–354 (2008).
- 42 Schouten O, van Domburg R, Bax J *et al.*: Noncardiac surgery after coronary stenting: early surgery and interruption of antiplatelet therapy are associated with an increase in major adverse cardiac events. *J. Am. Coll. Cardiol.* 49(1), 122–124 (2007).
- 43 Rabbitts J, Nuttall G, Brown M *et al.*: Cardiac risk of noncardiac surgery after percutaneous coronary intervention with drug-eluting stents. *Anesthesiology* 109(4), 596–604 (2008).
- 44 Godet G, Le Manach Y, Lesache F *et al.*: Drug-eluting stent thrombosis in patients undergoing non-cardiac surgery: is it always a problem? *Br. J. Anaesth.* 100(4), 472–477 (2008).
- 45 Assali A, Vaknin-Assa H, Lev E *et al.*: The risk of cardiac complications following noncardiac surgery in patients with drug eluting stents implanted at least six months before surgery. *Catheter. Cardiovasc. Interv.* 74(6), 837–843 (2009).